



PERCUTANEOUS NEPHROLITHOTOMY (PCNL) FOR THE TREATMENT OF UROLITHIASIS IN HORSESHOE KIDNEYS

Yousef SALAHHEDIN^{1,2}, Răzvan-Cosmin PETCA^{1,2}, Gabriel PREDOIU^{1,2}, Răzvan Alexandru DĂNĂU^{1,2}, Aida PETCA^{2,3}, Bogdan MASTALIER^{2,4}, Dumitru-Cristinel BADIU^{2,5}, Bogdan BRATICEVICI^{1,2}, Valentin Titus GRIGOREAN^{2,5} and Viorel JINGA^{1,2}

¹ Urology Department of the “Prof. Dr. Theodor Burghel” Clinical Hospital, Bucharest

² University of Medicine and Pharmacy “Carol Davila”, Bucharest

³ Department of Gynecology, “Elias” University Emergency Hospital, Bucharest

⁴ Department of General Surgery, “Colentina” Clinical Hospital, Bucharest

⁵ Department of General Surgery, “Bagdasar-Arseni” Clinical Emergency Hospital

Correspondence author: Răzvan-Cosmin PETCA

E-mail: drpetca@gmail.com

Accepted May 11, 2017

PCNL in horseshoe kidney (HSK) is a more complicated procedure. The purpose is to present the experience of a single, high volume, center in treatment of urolithiasis in HSK.

This study included patients between 2010 and 2016. 23 patients diagnosed with HSK, had 31 PCNL procedures on the same number of renal units due to the presence of bilateral stone disease. Statistical analysis of registered variables aimed to find potential risk factors for patients with stone disease, intra- and postoperative complications.

We had 19(82.6%) male and 4(17.4%) female patients. Bilateral PCNL was performed in 8(34.8%) cases. 15(65.2%) had either right or left lithiasis. Preoperative mean hemoglobin was 13.852 ± 1.53 g/dl, while postoperative was 11.717 ± 1.434 g/dl. Age is moderately correlated with an increase in hospital stay (Pearson's $R = 0.648$, $p < 0.001$). Intra or postoperative bleeding led to an increase in hospital stay (Pearson R of 0.664 with $p < 0.001$). Postoperative levels of serum creatinine showed a low to moderate correlation (Pearson's R : 0.475 and $p < 0.022$), 11 cases (47.8%) presented residual stone fragments.

Percutaneous surgery is an effective and safe treatment modality and can be improved by having a flexible nephroscope. Upper-pole access is relatively safe due to the inferior displacement, away from the pleura.

Key words: PCNL, Horseshoe kidney, fusion anomaly, kidney stone.

INTRODUCTION

Horseshoe kidneys (HSK) are the most common congenital renal fusion anomalies with a prevalence of 1/400. A recent review of more than 15,000 radiologic imaging studies revealed an incidence of 1 in 666 individuals¹. There are several variations in the basic shape of the horseshoe kidney. In 95% of cases, the kidneys join at the lower pole, which occurs before the kidneys have rotated on their long axes. The pelvis and ureters of the horseshoe kidney are usually anteriorly placed, crossing ventrally to the isthmus. The isthmus likely prevents cranial migration of the midportion of the renal mass beyond the inferior mesenteric artery. Anterior facing of the renal pelvis and the calyces more posteriorly than usual, make posterior percutaneous approach or ureteroscopic access to an isthmic calyx particularly difficult². The anatomic abnormalities

make the HSK prone to urinary stasis favoring both urinary precipitation and infections. Combined with metabolic abnormalities, these factors lead to stone formation.

Urolithiasis is the most common complication of horseshoe kidney, with a reported incidence of 21–60%. Minimally invasive surgery has a definitive role for treating urolithiasis associated with HSK. Shock wave lithotripsy, percutaneous nephrolithotomy (PCNL), ureteroscopy and laparoscopy have been successfully applied in patients with horseshoe kidney bearing stone³. In horseshoe kidneys the frontal plane lies more or less in the sagittal plane of the body. The posterior row is dorso-laterally and the renal pelvis is in a ventral position, offering a surprisingly good access to percutaneous nephrolithotomy. In selected centers that have access to flexible ureteroscopy, retrograde intra renal surgery is a treatment possibility.

Extracorporeal shock wave lithotripsy (ESWL) is the first line treatment modality for urolithiasis less

than 2 cm in a HSK⁴. However, for patients with large or otherwise complex stones, PCNL (percutaneous nephrolithotomy) is an effective procedure for the management. Many urologists regard PCNL in a horseshoe kidney as a more complicated procedure with a higher degree of complications compared with PCNL in normal kidneys. As a result, these patients may get over conservative treatment compromising their care and long-term renal function. The use of PCNL in congenitally anomalous kidneys, particularly horseshoe kidneys has received little attention in literature, possibly because of the percutaneous access problems and the higher incidents of complications with a lower success rate.

The purpose of the study is to present the experience of a single, high volume, center in the treatment of urolithiasis in HSK, to evaluate rate of complications and stone free rates.

MATERIAL AND METHODS

Between January 1th 2010 and February 1th 2016, our center treated a total number of 23 patients with horseshoe kidney and urolithiasis by performing PCNL. Out of the 23 patients with HSK, we had 31 PCNL procedures on the same

number of renal units due to the presence of bilateral stone disease.

The recorded variables were: patients age, gender, stone related factors (side, size on kidney, ureter and bladder (KUB) X-ray or computed tomography (CT), stone number and location, access site, and tract number), serum hemoglobin and creatinine level before and after procedure, duration of hospital stay and complications during and after the operation.

All patients underwent careful history taking and clinical examination. Renal function was assessed in all patients by measuring serum creatinine and the clearance. Imagistic investigations included plain abdominal X-ray (KUB) and gray-scale ultrasonography. Excretory urography (Figure 1) was performed if the serum creatinine was less than 2 mg/dL. If the stones were radiolucent, faintly opaque or difficult to localize by the previous methods, non-contrast spiral computed tomography (CT) was performed. The stone burden was determined by multiplying the stone length by the width in millimeters, squared, as measured on the preoperative KUB or excretory urography or CT in cases with radiolucent stones.

All PCNL procedures were performed by the urology team in a standard one-session technique with biplanary fluoroscopic guidance.

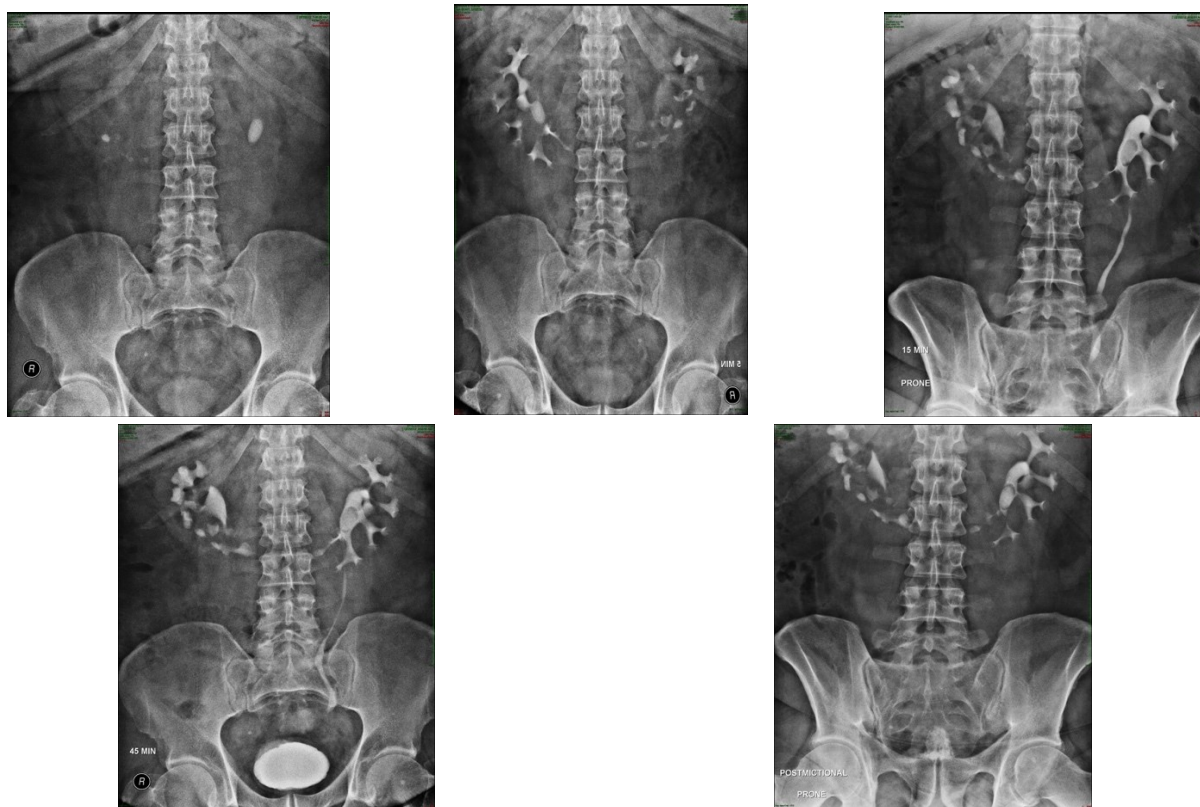


Figure 1. Intravenous urography showing a patient with horseshoe kidney and bilateral urolithiasis and hydronephrosis.

Percutaneous nephrolithotomy (PCNL) was performed in prone position with a subcostal access to the collecting system. The goal was to minimize number of access tracts and to obtain a stone free status of that renal unit. Access site was based on stone burden, stone location and collecting system configuration. The shortest trajectory from skin to collecting system was the goal. All procedures were done under general anaesthesia with intravenous antibiotic cover.

The procedure started with retrograde ureteric catheterization and delineation of pelvicalyceal (PVC) system with contrast while the patients were in lithotomy position. The patients were then placed in prone position for percutaneous renal access. Percutaneous renal access was established by the urologist under fluoroscopic guidance using the previously highlighted PVC system as a guide. The initial puncture was done by spinal needle (18G) followed by guide wire insertion (0.32G). This was followed by dilatation of tract by means of facial dilator (11Fr) and then by serial metallic dilators (from 9Fr to 27Fr). Finally Amplatz sheath of 28 Fr was placed through which 26 Fr nephroscope (Karl Storz™) was passed. Stone fragmentation was performed using pneumatic lithoclast (Swiss Lithoclast™) in all cases⁵. The fragmented pieces were removed by means of forceps. Postoperative drainage varied from case to case; hence all methods of drainage was used – double J stent, ureteral stent and nephrostomy. Double J stents were removed after 14 days, ureteral stents and nephrostomies were removed after 48 hours after surgery. After 24 hours postoperatively blood work was obtained and postoperative haemoglobin was noted along with postoperative blood urea-nitrogen and serum creatinine, followed by estimation of GFR using the MDRD II formula. 48 hours after surgery, stone free rate was evaluated by performing a KUB X-ray. After collecting the data we performed a statistical analysis using the SPSS v22 software.

RESULTS

From 2010 to 2016 we had 23 patients with horseshoe kidney that underwent PCNL for lithiasis in our service. This was a retrospective analysis of cases in our clinic. We had 19 (82.6%) male and 4 (17.4%) female patients that were diagnosed with HSK and lithiasis. The mean age was 46.913 ± 11.488 , with a minimum of 28 years and a

maximum of 67. Out of the 23 patients in our retrospective study, most of the patients had no personal history of illnesses (15 patients, 65.2%), the rest of the patients had comorbid conditions ranging from cardiovascular diseases to history of abdominal surgery and neurologic disorders. 14 of the subjects had no prior history of lithiasis and the rest of them had a history of lithiasis for which they received medication and/or underwent other surgical procedures then PCNL. Out of all our HSK patients we had 8 (34.8%) cases of bilateral stone disease, for which they underwent bilateral PCNL and we had 15 (65.2%) that had either right or left lithiasis (Figure 2).

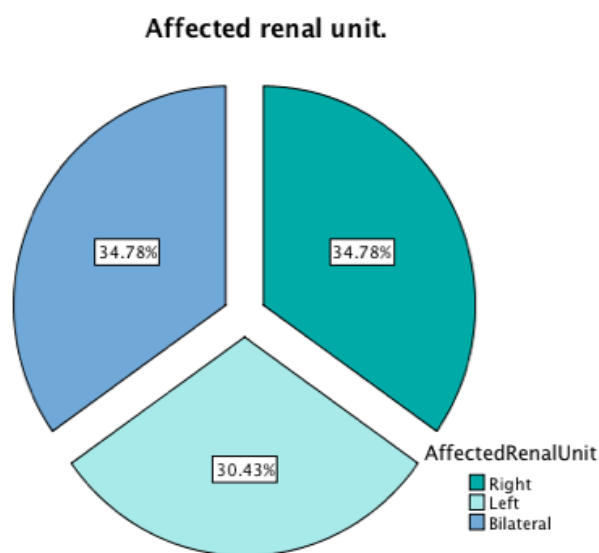


Figure 1. The affected renal units and the percent of bilateral stone disease.

As mentioned above, in all cases was performed PCNL – total of 31 procedures with a mean hospital stay of 8.56 ± 4.98 days. Preoperative mean haemoglobin was 13.852 ± 1.53 g/dl, while postoperative mean haemoglobin was 11.717 ± 1.434 g/dl. We also followed as a parameter the result of urine culture, so postoperative we had 4 patients with positive urine cultures for which they received antibiotics. Although we used antibiotic prophylaxis perioperative, we still found 3 cases of positive urine culture after extraction of all external catheters. We followed a series of parameters like preoperative and postoperative serum creatinine, calculated stone burden, all of which can be seen in Table 1.

Table 1

Basic statistical means and modes of study population

Statistics								
	Age	Hospital Stay	Preoperative Haemoglobin	Postoperative Haemoglobin	Preoperative Creatinine	Postoperative Creatinine	Stone Burden	
Mean	46,91	8,56	13,85	11,71	1,56	1,62	738,17	
Median	45,00	6,00	14,10	12,10	1,40	1,30	681,00	
Std. Deviation	11,48	4,98	1,53	1,43	0,75	0,82	404,08	
Minimum	28,00	4,00	11,10	8,90	0,80	0,90	281,00	
Maximum	67,00	19,00	16,50	13,70	4,50	4,30	1855,00	
Percentiles	25	40,00	5,00	12,70	10,40	1,10	1,10	467,00
	50	45,00	6,00	14,10	12,10	1,40	1,30	681,00
	75	58,00	12,00	14,80	12,80	1,80	2,30	819,00

We also followed a series of intraoperative parameters such as type of anesthesia, level at which PCNL tracts were created for access and type of urinary drainage.

Table 2

Access tracts and choice of drainage in the presented case series

PCNL Tract		Frequency	Percent
Valid	Superior Calix	16	51,61
	Middle Calix	8	25,8
	Inferior Calix	7	22,58
Drainage		Frequency	Percent
Valid	Ureteral Stent	13	41,9
	Double J Stent	18	58,1
	Total	31	100,0

As shown in Table 2, the most used way to access the upper urinary tract of HSK patients was

through the superior caliceal group in 14 (45,2%). We see that the double J stent was the most prevalent way to drain the upper urinary tract after end of PCNL, so we had 18 (58.1%) PCNL sessions that ended with insertions of double JJ stents.

Statistical analysis of registered variables aimed to find potential risk factors for patients with stone disease on horseshoe kidney for intra or postoperative complications. So we performed correlation tests of recorded variables and used hospital stay length as a predictor variable. We found that age of patient at the time of procedure is moderately correlated with an increase in hospital stay calculated Pearson's $R = 0.648$, $p < 0.001$. We also followed postoperative hemoglobin levels and correlated it with hospital stay and found that Pearson $R = 0.664$ with $p < 0.001$ showing that intra or postoperative bleeding led to an increase in hospital stay.

Analyzing postoperative levels of serum creatinine also showed a low to moderate correlation, with a Pearson's R of 0.475 and $p < 0.022$, showing that an increase of postoperative serum creatinine led to a prolonged hospital stay.

We had 11 cases (47.8%) which presented residual stone fragments at 48 hours postoperative seen on a KUB X-ray. Table 3 shows a crosstab representation of cases studied by grouping them on the basis of stone burden and the presence or absence of residual fragments on KUB X-ray.

Table 3

Crosstab representation of stone burden after grouping and the number of cases in which we had positive residual fragments, diagnosed of KUB X-ray

		Residual Fragments		Total
		No	Yes	
Stone Burden	<500	5	3	8
	501-1000	6	6	12
	>1501	1	2	3

We also recorded the development of intra- or perioperative complications and graded them in accordance to the modified Clavien-Dindo system of surgical complications. So we had 12 cases (52.2%) with no complications, grade I complications in 6 cases (26.1%), grade II in 3

patients (13%) and grade IIIa in 2 patients (8.7%)⁶. Figure 3 is a bar chart that represents Clavien graded complications by mean stone burden and gender of patients. Correlation analysis of stone burden and complications has no statistical significance with $p = 0.727$.

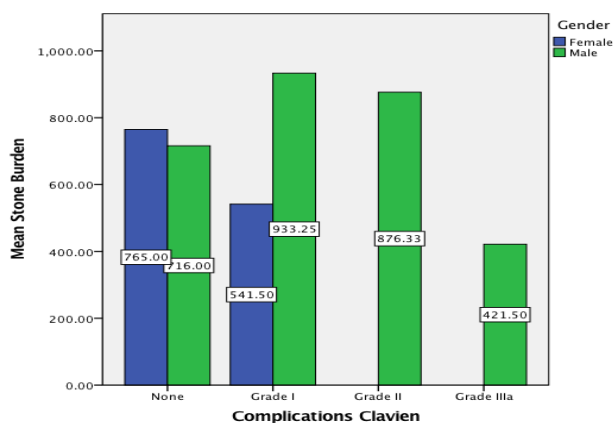


Figure 2. Recorded complications relative to mean stone burden and color coded by color.

One of our hypothesis was to see if the complications we had in the study population were influenced by stone burden. We performed a Oneway ANOVA and found that there is no statistical significance while testing our hypothesis $F(2,19) = 0.546$, $p < 0.657$. This means that stone burden was not the cause for complications.

DISCUSSIONS

Urolithiasis is the most common complication of horseshoe kidney. Percutaneous surgery is established as an effective and safe treatment modality^{3,7}. The first attempt to achieve percutaneous access to a horseshoe kidney was reported by Fletcher and Kettewell in 1973; since then, PCNL in horseshoe kidneys has been considered the standard of care for stones of 1–2 cm, or for stones in which ESWL has failed⁷. Overall the renal stone burden is higher in anomalous kidneys than in normal ones⁶.

In patients with normal renal anatomy, access to the upper pole calyces during PCNL often requires a supracostal approach, with the associated risk of pleural injury. PCNL in horseshoe kidneys differs from normal kidneys owing to the challenges encountered because of the abnormal caliceal orientation and aberrant vasculature, usually being oriented dorsomedially or dorsolaterally. Medially

placed tracts are more difficult to dilate because they traverse through the erector spinae and quadratus lumborum muscles. However, in the horseshoe kidney upper-pole access is relatively safe due to the inferior displacement of the kidneys away from the pleura. Furthermore, upper-pole access is a valuable aid to stone clearance, as the alignment of the nephroscope with the long axis of the kidney aids manipulation of the scope into the upper calyces, renal pelvis, lower calyces, PUJ and proximal ureter. Our experience confirms the safety of the upper pole approach to the horseshoe kidney, as we reported 14 cases (42.5%) of upper pole access without any pleural involvement in the study group^{8,9}. The prone position allows upper pole puncture to be performed more easily. It allows access to the upper pole, renal pelvis, lower pole calyces, pelviureteral junction and proximal ureter. Most important it is closer to the skin respecting a fundamental principle of PCNL to take the shortest route. The vascular issues regarding anomalous kidneys consisting in avoiding aberrant vessels, trend towards the use of both fluoroscopy and ultrasonography to guide the puncture. Other guidance techniques used with PCNL also include laparoscopy, which permit direct visualisation and safe puncture tract placement¹⁰. Laparoscopic assisted PCNL was successfully used in approach of ectopic pelvic kidneys. Horseshoe kidneys are frequently associated with uretero-pelvic obstruction, one may consider laparoscopic approach in this circumstances and combine stone removal with uretero-pyeloplasty¹⁰.

We would like to note that in 7 cases (22.58%) of cases we had to perform an inferior pole access which is very hard to do in horseshoe kidneys. To correctly evaluate the stone free rates of procedures we should have performed low dose CT to all patients¹¹. Due to shortages in the system we only had access to KUB X-ray to evaluate our results. By doing this we reported that 11 patients had residual fragments at 48 hours after procedure. This makes our stone free rate to be somewhat lower compared to other similar works^{7,9,12}. The absence of a flexible nephroscope is probably one of the reasons for this low stone free rate. Also the low clearance rate should be evaluated by using CT scans after PCNL¹¹.

There are a number of studies in the literature that show increased results by using flexible and long nephroscopes, although our study didn't manage to prove this point we speculate that it is so². Full radiologic evaluation and surgical planning

are essential in all PCNL cases. The choice of caliceal puncture should be selected according to each renal unit, for example the establishment of the nephrostomy tract more inferior and medial position than normal. Our series highlights the fact that PCNL in horseshoe kidneys does not require any special preoperative investigation or intraoperative care provided that the surgeon is experienced enough. All punctures were done by a urologist under standard fluoroscopic guidance we do not feel that CT guidance is necessary as suggested by some authors¹³. Renal function of horseshoe kidney patients was found in our study to increase hospital stay, although we have not found any data for comparison in the reviewed literature^{7,8,11,14,15}. Regarding renal function we could not draw any conclusions due to the study design, scintigraphic evaluation of renal function and a prospective approach to include follow up visits.

All cases were done by subcostal approach and we had 14 upper calyx punctures, 6 to the middle and 11 to the inferior. In past study on PCNL complications in patients with normal kidney anatomy done in our centre we had a reported complications rate of 29% comparable to our 35,48% in this series^{6,16}.

CONCLUSIONS

In conclusion PCNL used in patients with high stone burden and horseshoe kidney is relatively safe procedure for HSK patients and it can be improved by having a flexible nephroscope. In our experience there is no need for CT puncture of the collecting system. We also found that older HSK patients with a bigger stone burden will potentially have some more intra- and/or postoperative complications. Because of subcostal access, no pulmonary complication occurred.

REFERENCES

1. Weizer A.Z.; Silverstein A.D.; Auge B.K.; Delvecchio F.C.; Raj G.; Albala D.M.; Leder R.; Preminger G.M., *Determining the incidence of horseshoe kidney from radiographic data at a single institution. J Urol*, **2003**, *170*(5), 1722-6.
2. Raj G.V.; Auge B.K.; Weizer A.Z.; Denstedt J.D.; Watterson J.D.; Beiko D.T.; Assimos D.G.; Preminger G.M., *Percutaneous management of calculi within horseshoe kidneys. J Urol*, **2003**, *170*(1), 48-51.
3. Yohannes P.; Smith A.D., *The endourological management of complications associated with horseshoe kidney. J Urol*, **2002**, *168*(1), 5-8.
4. Kirkali Z.; Esen A.A.; Mungan M.U., *Effectiveness of extracorporeal shockwave lithotripsy in the management of stone-bearing horseshoe kidneys. J Endourol*, **1996**, *10*(1), 13-5.
5. Razvi S.; Zaidi Z., *Percutaneous nephrolithotomy (PCNL) in horse shoe kidneys. J Pak Med Assoc*, **2007**, *57*(5), 222-225.
6. Braticevici B.; Salahhedin Y.; Ambert V.; Petca R.C.; Diaconescu D.; Rascu S.; Jinga V., *Complications of percutaneous nephrolithotomy classified by the modified clavien grading system a single centers experience over 18 months. Revista Română De Urologie*, **2014**, *13*(1), 18-22.
7. Viola D.; Anagnostou T.; Thompson T.J.; Smith G.; Moussa S.A.; Tolley D.A., *Sixteen years of experience with stone management in horseshoe kidneys. Urol Int*, **2007**, *78*(3), 214-8.
8. Miller N.L.; Matlaga B.R.; Handa S.E.; Munch L.C.; Lingeman J.E., *The presence of horseshoe kidney does not affect the outcome of percutaneous nephrolithotomy. J Endourol*, **2008**, *22*(6), 1219-25.
9. Symons S.J.; Ramachandran A.; Kurien A.; Baiysha R.; Desai M.R., *Urolithiasis in the horseshoe kidney: a single-centre experience. BJU Int*, **2008**, *102*(11), 1676-80.
10. Osther P.J.; Razvi H.; Liatsikos E.; Averch T.; Crisci A.; Garcia J.L.; Mandal A.; De La Rosette J., *Percutaneous nephrolithotomy among patients with renal anomalies: patient characteristics and outcomes; a subgroup analysis of the clinical research office of the endourological society global percutaneous nephrolithotomy study. J Endourol*, **2011**, *25*(10), 1627-32.
11. El Ghoneimy M.N.; Koder A.S.; Emran A.M.; Orban T.Z.; Shaban A.M.; El Gammal M.M., *Percutaneous nephrolithotomy in horseshoe kidneys: is rigid nephroscopy sufficient tool for complete clearance? A case series study. BMC Urol*, **2009**, *9*, 17.
12. Skolarikos A.; Binbay M.; Bisas A.; Sari E.; Bourdounis A.; Tefekli A.; Muslumanoglu A.Y.; Deliveliotis C., *Percutaneous nephrolithotomy in horseshoe kidneys: factors affecting stone-free rate. J Urol*, **2011**, *186*(5), 1894-8.
13. Al-Otaibi K.; Hosking D.H., *Percutaneous stone removal in horseshoe kidneys. J Urol*, **1999**, *162*(3), 674-7.
14. Mosavi-Bahar S.H.; Amirzargar M.A.; Rahnavardi M.; Moghaddam S.M.; Babbohavaeji H.; Amirhasani S., *Percutaneous nephrolithotomy in patients with kidney malformations. J Endourol*, **2007**, *21*(5), 520-4.
15. Ozden E.; Bilen C.Y.; Mercimek M.N.; Tan B.; Sarikaya S.; Sahin A., *Horseshoe kidney: does it really have any negative impact on surgical outcomes of percutaneous nephrolithotomy? Urology*, **2010**, *75*(5), 1049-52.
16. Tanase F.; Braticevici B.; Salahhedin Y.; Petca R.; Radavoi G.D.; Pascu M.; Jinga V., *C164: Percutaneous nephrolithotomy in horseshoe kidney: Single center experience over 4 years. European Urology Supplements*, **2014**, *13*(6), e1344.