

## NEW TEAM, REHABILITATION AND ORTHOPEDIC, APPROACHES OF PATIENTS WITH MENISCAL LESIONS

Cristina DAIA<sup>1,2</sup>, Gelu ONOSE<sup>1,2</sup>, F. BICA<sup>1,2</sup> and R. BADEA<sup>1,2</sup>

<sup>1</sup>The University of Medicine and Pharmacy "Carol Davila", Bucharest, Romania

<sup>2</sup>The Teaching Emergency Hospital "BagdasarArseni", Bucharest, Romania

*Corresponding author:* Assist. Prof. Cristina Daia, MD, PhD, The Teaching Emergency Hospital "BagdasarArseni", Bucharest, Romania; mobile phone +40723318151; e-mail cristdaia@yahoo.com

*Accepted May 30, 2018*

*Objective:* We analyzed in a retrospective study, 132 patients over the age of 18 years, diagnosis with meniscal lesion at admission, hospitalized between 01.01.2017 and 12.31.2017 in the Orthopedic division of the Teaching Emergency Hospital BagdasarArseni.

*Methods:* We evaluated the patient's degree of activity, the cause of the meniscus lesion, types of meniscus lesions, types of surgery, pain on the visual analog scale (VAS) scale, the amplitude of movement, range of motion, range of motion (ROM) of the knee (flexion, extension, rotation) at admission, at discharge, every day of the first week, then at 3, 6, 10 and 12 weeks after surgery.

*Results:* Our study included 76 male and 56 female patients of age ranging from 18 to 62 (72 patients under the age of 35, 60 over 35 yo). At admission 96 patients were diagnosed with longitudinal or radial meniscal lesions due to traumatic events and 36 were diagnosed with degenerative meniscal lesions due to minimal rotatory trauma or stress in association with arthrosis. Arthroscopic surgery was the procedure of choice for all patients included in the study. 84 patients with meniscal tears due to trauma received arthroscopic suture and 12 received suture and partial meniscus removal. 36 patients with degenerative meniscal tears had arthroscopic partial meniscectomy. At admission, patients presented pain between 3 and 7 on pain VAS and range of motion deficit due to pain (flexion deficit 20–30 degrees, extension deficit 5–10 degrees). 18 patients presented "locked knee". At discharge the pain ranged 2–3 on VAS for patients who received suture and 0–1 for patients with meniscus partial removal. All patients began recovery program second day after surgery. Performance sports patients who had meniscectomy procedure regained full knee movement and began training at 4–6 weeks and those who had suture regained full knee movement at 9–10 weeks and began training 10–12 weeks. Proactive patients with meniscectomy treatment returned to normal activity 10–14 days after surgery and those with suture returned 21–30 days after surgery. Postoperative recovery time vary with the degree of associated cartilage lesions.

*Conclusions:* Proactive / performance sports patients, victims of a sports accident most commonly suffer from meniscus injuries. The combination of drug therapy, surgical methods and recovery program lead to significant improvement in pain and functionality, respectively, to optimal parameters.

*Keywords:* rehabilitation, orthopedic treatment, meniscal lesion, surgical repair.

### 1. INTRODUCTION

Meniscal lesions are common in the general population, whether the knee is symptomatic or not.

The mean annual incidence of meniscal lesions in USA per 10,000 inhabitants 4.0 in general population, 9.0 in males and 4.2 in females, and 8.27 for active population per 1000 person-years [1].

Depending on the patient's age, a prevalence of up to 36% has been reported in a meta-analysis based on 22 studies described an overall sensitivity

of 88% and specificity of 94% for detecting meniscal lesions [2].

To our knowledge, this is the largest population-based study to examine the incidence of meniscal tears within a physically active population that is at elevated risk of sport and training-related knee injuries adolescents playing sports that involve pivoting, such as football, soccer, basketball, team handball or even tennis. Young women have a 3 to 5 times higher risk of this injury than men when participating in these sports [3].

The main risk factors for meniscal lesions are: acute (micro) trauma (twisting injury), knee joint

arthritis, knee instability, anterior cruciate ligament (ACL) injury, age, family history, work or leisure activities, muscle weakness, obesity. After 2 or 3 day after a click trauma, knee pain, particularly along the joint line occurs. There are described also swelling, stiffness, knee locking, instability, limited range of motion. The degree of meniscus vascularization is directly related to the healing potential of the meniscus. Practically a meniscus rupture in red-red and red white areas cannot be properly healed, so it should be removed arthroscopically. Keeping the affected meniscus in the area will cause premature aging of the joint and, in a few years, knee osteoarthritis [4]. Meniscal lesions are common in the general population, whether the knee is symptomatic or not. Horizontal or oblique meniscal tears are frequently encountered in both asymptomatic and symptomatic knees and may not always be related to symptoms. However, radial, vertical, complex, or displaced meniscal tears and abnormalities of the collateral ligaments, pericapsular soft tissues, and bone marrow are found almost exclusively on the symptomatic side and appear to be clinically more meaningful [2, 5].

After physical exam some common imaging tests could be done: ultrasound (almost 10% of the lateral menisci could not be evaluated because of poor images appears to be a weakness of ultrasound), magnetic resonance imaging, MRI, (differ for medial and lateral meniscus and ACL, with only 85% accuracy). Arthroscopy is gold standard. It is a minimally invasive surgical procedure used to evaluate and treat injuries inside the joints. For example, we can detect cartilage lesions, such as meniscal knee ruptures that occur frequently in active young athletes, or ligaments ruptures, such as ACL. These are the main breaks encountered by footballers or swimmers (handball players, basketball players or skiers). Chronic synovitis, knee osteophytes (removal) and knee osteoarthritis can be also detected [6].

## 2. MATERIAL AND METHOD

Therapeutical approach for meniscal lesions are conservative, surgical, or combined.

Conservative treatment is applied to: stable longitudinal (less than 1 cm) or incomplete meniscus tear [7]. It consists of: (1) immobilization in the gypsum pad or orthosis for 2 weeks, (2) medication: administration of anti-inflammatory drugs, (3) local ice application, (4) rehabilitation program: physiotherapy, followed by 12 weeks of kinetotherapy.

Degenerative meniscal lesions are very common findings which can be considered as an early stage of osteoarthritis in middle-aged patients. Recent randomized studies found that arthroscopic partial meniscectomy has no superiority over non-operative treatment.

Thus, non-operative treatment i.e physiotherapy should be the first-line choice and APM should be considered in case of failure: three months has been accepted as a threshold in the ESSKA Meniscus Consensus Project presented in 2016 [7]. Earlier indications may be proposed in cases with considerable mechanical symptoms. Surgical arthroscopic technique is the ideal solution for the treatment of meniscus lesion which is minimally invasive [8], with 24 hour hospitalization (one day surgery), it has rapid recovery in 2 to 4 weeks and involves progressive postoperative rehabilitation (physiotherapy, kinetotherapy) and medical treatment: analgic, anti-inflammatory and antibiotics treatment (mild antibacterial treatment for 5–7 days).

However, the meniscectomy rate remains too high even though robust scientific publications indicate the value of meniscal repair or non-removal in traumatic tears and non-operative treatment rather than meniscectomy especially in degenerative meniscal lesions. In traumatic tears, the first-line of choice is repair or non-removal [7].

There are three types of sutures [7, 9]: (1) Inside-out: suture threads are directed from the inside of the knee to the periphery; (2) Outside-in: it's easy in the case of the 2/3 previous rupture of the meniscus and difficult for hip fractures; (3) All inside: addresses only to 1/3 tears.

Longitudinal vertical tears are a proper indication for repair, especially in the red-white or red-red zones. Success rate is high and cartilage preservation has been proven [7].

Non-removal can be discussed for stable asymptomatic lateral meniscal tears in conjunction with ACL reconstruction. Extended indications are now recommended for some specific conditions: (1) horizontal cleavage tears in young athletes, (2) hidden posterior capsulo-meniscal tears in ACL injuries, (3) radial tears and root tears [7, 10].

In chronic pain the surgical repair/ suture has no indication of cartilage deterioration, which is diffused, extensive and progressive.

For complex lesions that can not be repaired (cleavage, degenerative, flap), the main goal is external meniscal preservation with a main risk assumed: knee arthrosis. Meniscectomy is one of the most popular orthopedic procedures, but long-

term results are not entirely satisfactory and the concept of meniscal preservation has therefore progressed over the years [7, 11].

Rehabilitation program has a specific aim: to accelerate the healing of teared structures.

First of all we use a specific physiotherapy method: DIAPULSE. Its effects are: (1) to activate the local anabolic processes, (2) vasculo-trophic, and (3) resorptive. The time of Diapulse application is 10 minutes, on injured knee. We applied 10 consecutive sessions.

We combine physiotherapy with kinetotherapy. The major aims are: (1) dynamic control of locomotion (2) to eliminate locomotor dysfunction action (3) to increase knee stability, (4) mobility and (5) muscular strength. Kinetotherapy means are: techniques, exercises, and methods.

We structured the kinetic program on 4 phases.

Phase I, called the initiation was in the first 2 weeks.

For knee stability, in phase 1, were selected the following exercises that were repeated each of them 8 to 16 times:

(1) isometry of quadriceps and hamstrings: from dorsal decubitus, knee bent at about 30 degrees, fix the lower limb to the heel, contract the thigh muscles for 6 seconds, then relax.

(2) isometry of quadriceps: from ventral decubitus the ankle (on the knee-operated side) with a towel rolled, decubitus knee bent at about 30 degrees, push the ankle down, trying to touch the floor.

(3) isometry of gluteus maximus muscle: from dorsal decubitus, knee bent at about 30 degrees, fix the lower limb to the heel and contract your gluteus maximus muscles for 6 seconds, then relax.

For affected knee mobility patients from dorsal decubitus made slow flexion/extension of the knee, 8 to 16 rehearsals. For homolateral hip patients from dorsal decubitus made flexion/extension of the hip with knee flexed at 30 degrees.

Finally from the orthostatic position, patients made mobilisation of the hip and affected knee.

In phase II, from 2 to 4 weeks, by adding progressive some weight on the ankle corresponding to affected knee, we continued with exercises for stability, also 8 to 16 rehearsals.

1. Working with extended knee from dorsal decubitus patients made quadriceps isometry from 6 seconds, then relax.

2. Partial squats, for 30 degrees until 30 days from the surgery, then at 60 days maximum 90 degrees of squats (phase IV).

In phase III after 30 days, some exercises were selected. First from orthostatic position patients

bended the affected knee 30 degrees to maximum 45 and maintained. Also there were selected up and down stairs exercises for the affected leg. The high stair level was maximum 15 cm for start.

From supine position with extended knee quadriceps isometry 6 sec, then relax. Hamstring stretching were selected for this phase too.

After 4 weeks ergometric bicycle exercises were started with a progressive period of time and load, starting with 5 minutes, maximum of 20 minutes/day; minimum 3 times/week.

Walking as exercise was started after 2 weeks. It is very good at the middle stage of recovery (two weeks after surgery), but is ideal in stage III.

Phase IV after 60 days (8 weeks) started with running as rehabilitation exercise.

Running should be avoided for the first 6–8 weeks after surgery, ideal to be gradually introduced into the exercise program after 60 days.

After we obtained the Hospital Ethic Commission approval No 1208/15.05.2018 we analyzed in a retrospective study, 132 patients, over 18 years old, diagnosed with meniscal lesion, hospitalized between 1st January 2017 and 31 December 2017 in the Orthopedic division of the Teaching Emergency Hospital Bagdasar Arseni.

Arthroscopic surgery was the procedure of choice for all patients included in the study.

We evaluated the patient's degree of activity, the cause of the meniscus lesion, types of meniscus lesions, types of surgery, pain on the visual analog scale (VAS), the amplitude of movement, ROM of the knee (flexion, extension) at admission, and every day of the first week, then at 3, 6, 10 and 12 weeks after surgery.

### 3. RESULTS

#### Demographic data

– Age distribution : min age 18, max age 62 year old, y.o, mean age 35 years old, standard deviation, SD, 11.18;

– Gender distribution: Male/Female, number 76 male and 56 female. Raport Male/Female= 1.35/1;

– Residence: city/country, 73 patients with city residence, the other 59 were from country. Raport city/country =1.23;

Patients' level of activity was: 11% sedentary, 75% normal and 14% had performance in sport;

The causes of the meniscus lesion were: traumatic tear 70%, degenerative 27% and both 3%;

Types of meniscus lesions were: longitudinal or radial meniscal lesions 96 cases and minimal rotatory trauma or stress in association with degenerative meniscal lesions 36 cases;

Types of surgery made were: meniscectomy 27%, surgical repair 64% , both 9%;

The analyses of pain on VAS scale (Table 1, Figure 1) show statistical significant result of decreasing pain at 12 weeks, from an average of 4.74 points to 1.94.

The amplitude of movement, range of motion, ROM of the knee (flexion, extension, rotation) at admission, and at 3, 6, 10, 12 weeks were statistical significant improved (Table 2).

*Table 1*  
The VAS analyze

	Admission	VAS 12 weeks after surgery
VAS max	7	3
VAS min	3	0
Mean	4.74	1.94
P-value	0.0001	

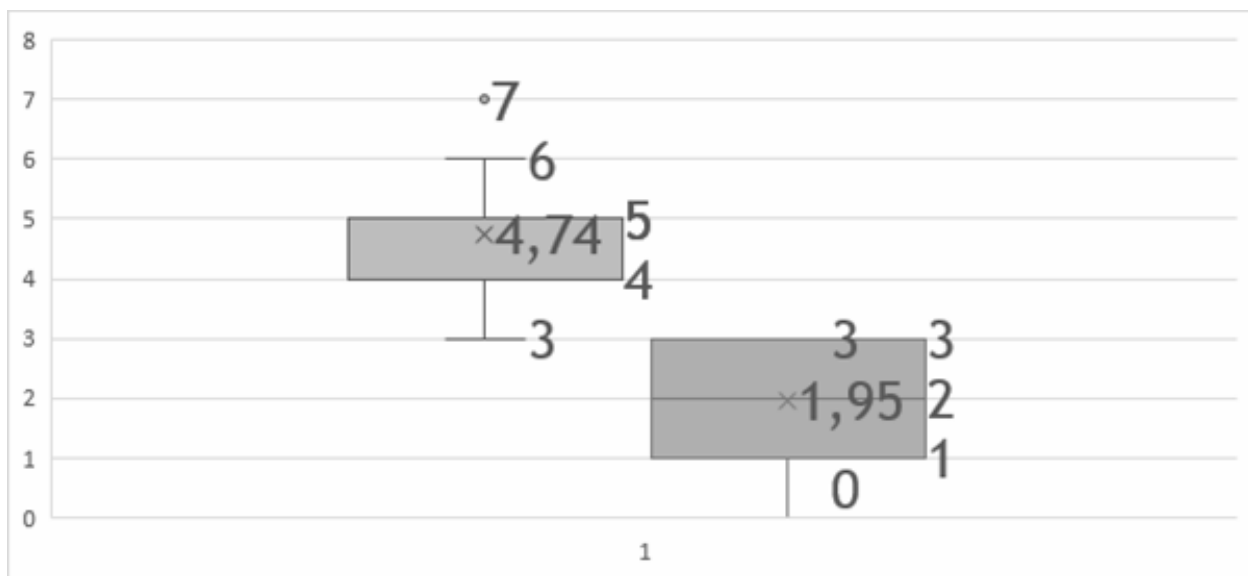


Figure 1. VAS – box and whisker plot.

*Table 2*  
ROM analyze

	Admission	3 weeks	6 weeks	10 weeks	12 weeks	p
ROM Flexion	26	18	19	8	1	<0.001
ROM Extension	8	6	5	3	0	<0.001

#### 4. DISCUSSION AND CONCLUSION

We observed that pain is slightly increased during the first three days after surgery for patients with meniscal suture as opposed to patients with partial meniscectomy where pain usually lasted for 24 hours after surgery.

In general meniscal lesions affect adult males 35 years old with normal level of activity, most commonly suffer from longitudinal or radial meniscal lesion injuries (70%). The surgical repair is the main method chosen to treat meniscal lesions (73%). Pain and functionality were statistically significant improved ( $p < 0.001$ ).

These good results are sustained by the good collaboration between orthopedy and rehabilitation. A good surgical approach followed by specific rehabilitation program described above lead to very good results and encouraged us to share our experience.

The association of drug therapy, surgical methods and rehabilitation program lead to significant improvement in pain and functionality, respectively, to optimal parameters.

## REFERENCES

1. J Jones, R Burks, B Owens, R Sturdivant, S Svoboda, K Cameron, *Incidence and Risk Factors Associated with Meniscal Injuries Among Active-Duty US Military Service Members*, J Athl Train, 2012; 47(1): 67–73.
2. M Zanetti, C Pfirrmann, M Schmid, J R Burkhardt, S J Hodler, *Patients with Suspected Meniscal Tears: Prevalence of Abnormalities Seen on MRI of 100 Symptomatic and 100 Contralateral Asymptomatic Knees*, American Journal of Roentgenology. 2003;181: 635–641.
3. A Hedel, D Jensen, P Blyme, S Sonne-Holm, *Epidemiology of meniscal lesions in the knee 1,215 open operations in Copenhagen 1982–84*, AcfaOrthor, Scand 1990; 61 (5): 435–437.
4. S Lohmander, M Englund, L Dahl, E Roos, *The Long-term Consequence of Anterior Cruciate Ligament and Meniscus Injuries*, J. Sports Med.2007;10:35.
5. N Bolog, G Andreisek, *Reporting knee meniscal tears: technical aspects, typical pitfalls and how to avoid them*. *Insights Imaging*. 2016 Jun; 7(3): 385–398.
6. Y Akatsu, S Yamaguchi, S Mukoyama, T Morikawa, T Yamaguchi *et al.*, *Accuracy of high-resolution ultrasound in the detection of meniscal tears and determination of the visible area of menisci*. J Bone Joint Surg Am. 2015; 20; 97(10):799–806.
7. P Beaufils, R Becker, S Kopf, O Matthieu, N Pujol, *The knee meniscus: management of traumatic tears and degenerative lesions*. Efort Open Rev. 2017;2(5):195–203.
8. J Vaquero, F Forriol, *Meniscus tear surgery and meniscus replacement*, Muscles Ligaments Tendons J. 2016; 6(1):71–89.
9. D Cohen, T Wickiewicz, *The outside-in technique for arthroscopic meniscal repair*, Oper Tech Sports Med. 2003; 11(2):91–103.
10. S Mordecai, N Al-Hadithy, H Ware, C Gupte, *Treatment of meniscal tears: An evidence based approach*, World J Orthop. 2014 Jul 18; 5(3): 233–241.
11. T Kamimura, M Kimura, *Meniscal Repair of Degenerative Horizontal Cleavage Tears Using Fibrin Clots*, Orthop J Sports Med. 2014 Nov; 2(11).

